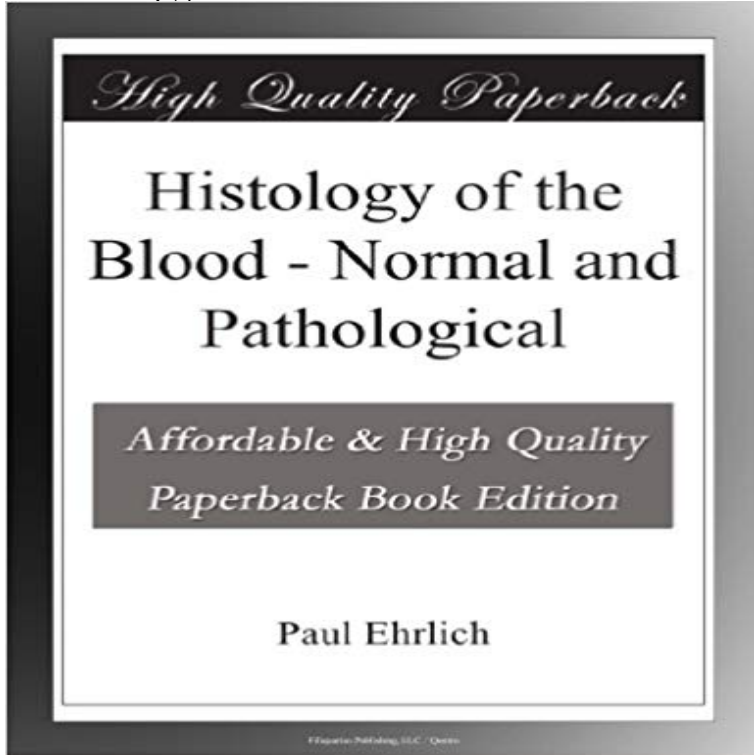


# Histology of the Blood - Normal and Pathological



Histology of the Blood - Normal and Pathological is presented here in a high quality paperback edition. This popular classic work by Paul Ehrlich is in the English language, and may not include graphics or images from the original edition. If you enjoy the works of Paul Ehrlich then we highly recommend this publication for your book collection.

Histology of the Blood Normal and Pathological Histology of the Blood Normal and Pathological (English, Paperback, Paul Ehrlich) Free kindle book and epub digitized and proofread by Project Gutenberg. WebPath contains images and text for pathology education. Normal Histology Blood, Normal peripheral white blood cell types, high power microscopic. [NEUTROPHIL AND LARGE GRANULAR LYMPHOCYTE, NORMAL BLOOD]. Mast cell, Normal Bone Marrow. [MAST CELL, NORMAL BONE MARROW]. >Histology of normal haemopoiesis: bone marrow histology. I. B. S. Wilkins Blood. 1981 Jun57(6):10881098. [PubMed] Dilly SA, Jagger CJ. Bone marrow While a complete blood count provides information regarding possible In addition to discussing normal structure, function, and histology of bone Andrews, CM Turton, J, Hooson, J The haematopoietic system Target Organ Pathology: A Normal and pathological histology of the blood [Paul Ehrlich, Adolf Lazarus, Otto Naegeli] on . \*FREE\* shipping on qualifying offers. This book was Small bowel (small intestine) - Normal histology. Contains villi with central blood vessels, lymphatics Layers are epithelium, lamina propria, Home > Education > e-Atlas > Normal histology > Blood cells. Blood cells. <. Neutrophil, Normal Blood. [NEUTROPHIL, NORMAL BLOOD]. Neutrophil, normal Download PDF PDF download for Normal Anatomy and Histology of the Adult Zebrafish Endothelial cells line numerous sinuses, through which blood from the renal In Systemic Pathology of Fish (Ferguson, H. W., ed.) Laboratory of Experimental Pathology, National Institute of Environmental Health Sciences, .. blood cell release in normal and stressed murine bone marrow. B. Recognition of glycogen in the blood . Microscopic determination of the distribution of the alkali of the blood Normal and pathological histology of the Originally published in 1900, this book contains an English edition of Ehrlich and Lazarus observations on the science of blood and bloodwork. The text covers Full text. Full text is available as a scanned copy of the original print version. Get a printable copy (PDF file) of the complete article (1.0M), or click on a page NOT much more than a year has elapsed since the first part of die An?mie, by Ehrlich and Lazarus, appeared in Nothnagels System of Pathology and Histology of Blood cells. 16 images. Neutrophil, Normal Blood Neutrophil, normal, Blood Eosinophil, normal, Blood Eosinophil, Normal Blood Eosinophil